



# What's New in Sports Medicine

May 19, 2022


Ogden Surgical – Medical Society Conference

*Anthony Beutler, MD*

*Associate Medical Director & Fellowship Director, Sports Med  
Intermountain Healthcare*

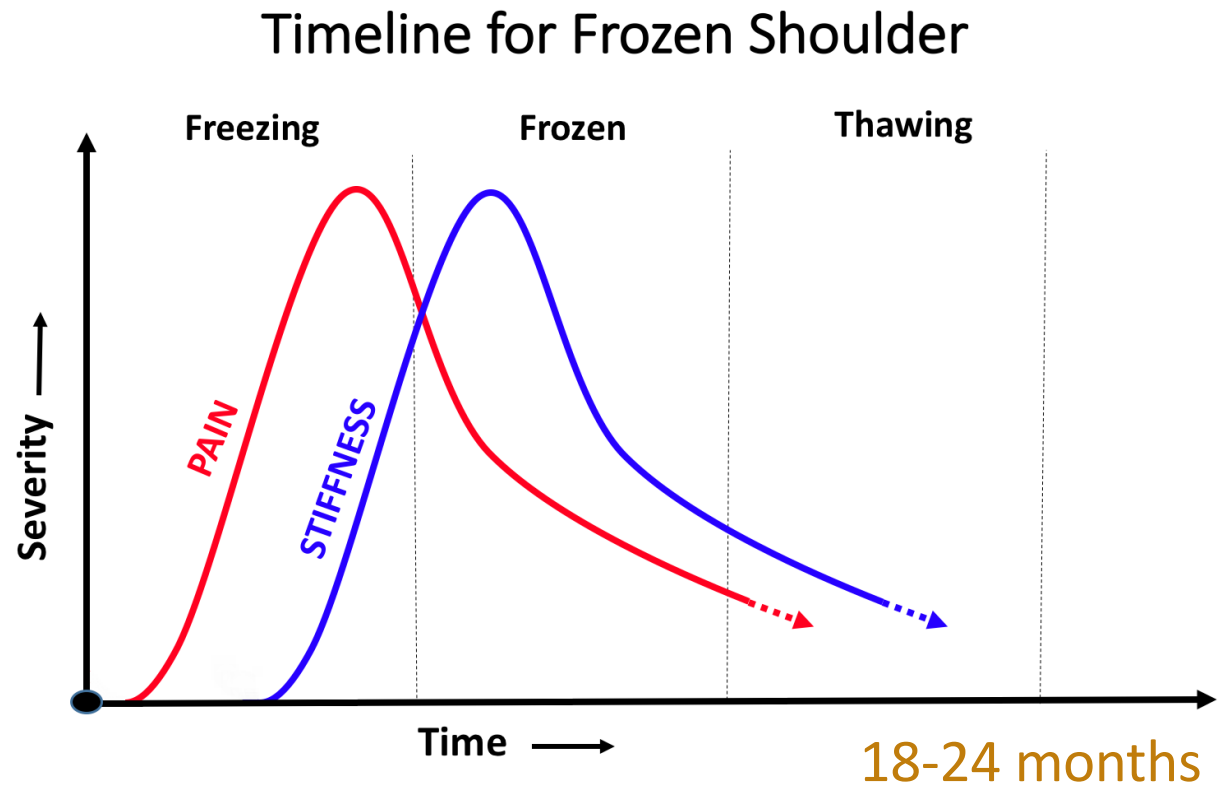
# What's New in Sports Medicine

- Hydrodilatation for Frozen Shoulder
- Posterior Interosseus Nerve Entrapment
- Platelet Rich Plasma Best Practices



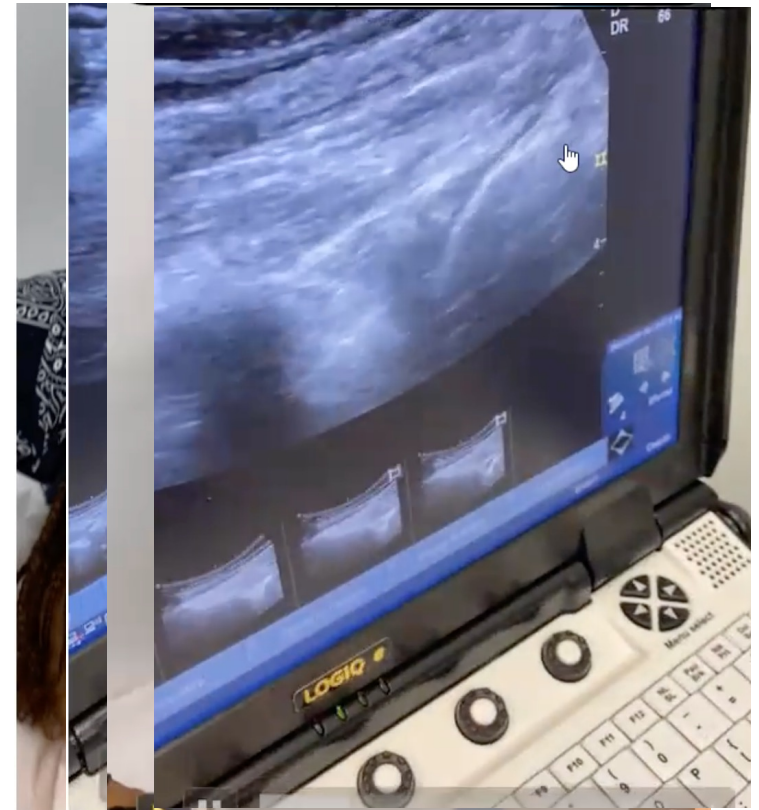
# Time Course of Frozen Shoulder: What to Do?

- Physical Therapy?
- Manual Therapy?
- Operative lysis of adhesions?
- Injection (steroid, other?)
- Organic Bear Snot?



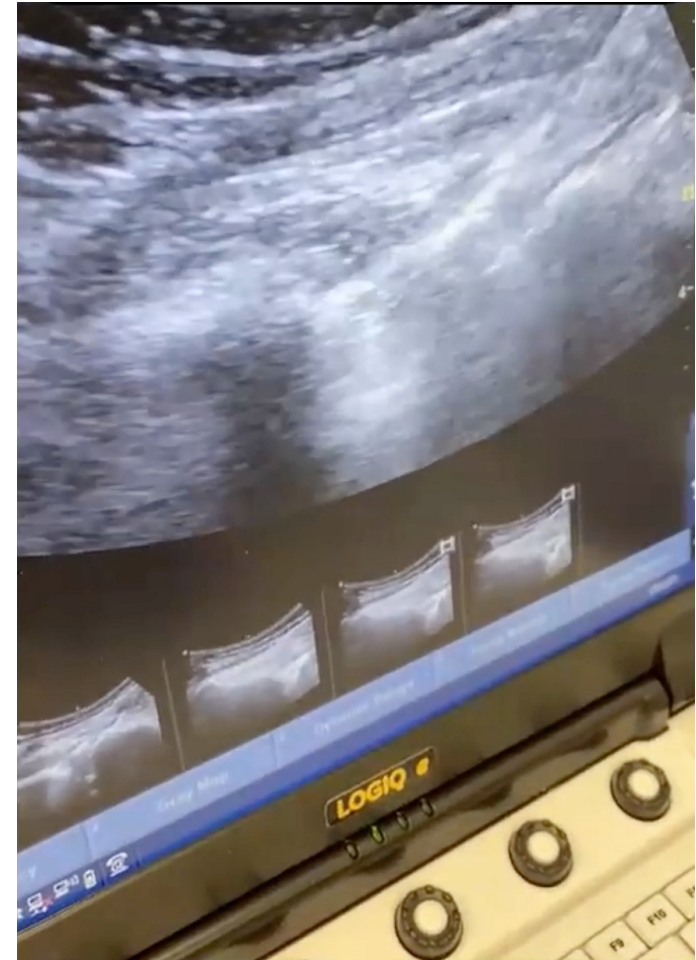# Hydrodilatation for Frozen Shoulder

- Office-based procedure
  - Suprascapular nerve block (therapeutic/anesthetic)
  - High volume, ultrasound guided, glenohumeral injection



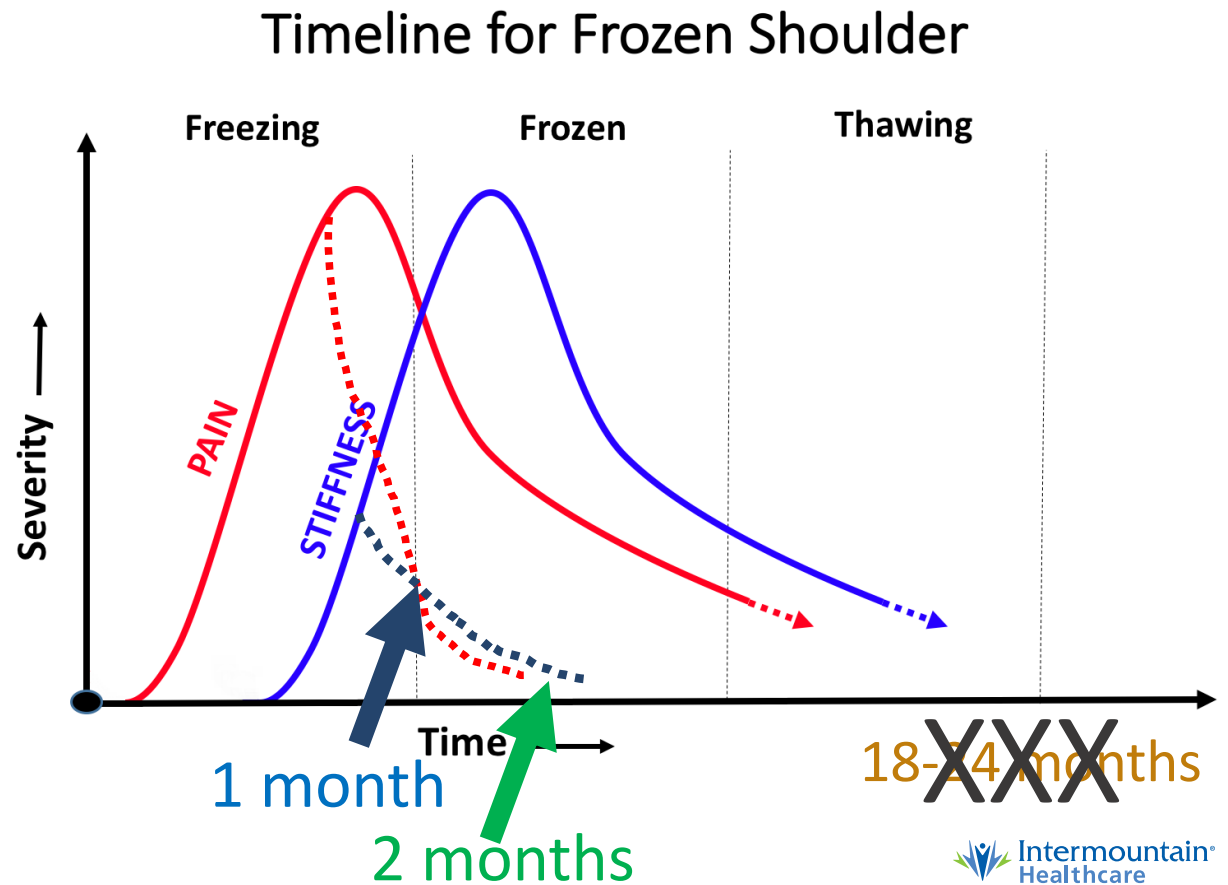
# Hydrodilatation for Frozen Shoulder

- Office-based procedure
  - Suprascapular nerve block (therapeutic/anesthetic)
  - High volume, ultrasound guided, glenohumeral injection
- Immediate manual ROM
- Same day Physical Therapy appointment
- Daily Home Pulley Exercises




# Time Course of Frozen Shoulder: What to Do?

- One Month Post:
  - 90% pain decrease
  - 50% stiff decrease
- Two Months Post:
  - 98% pain decrease
  - 90% stiff decrease



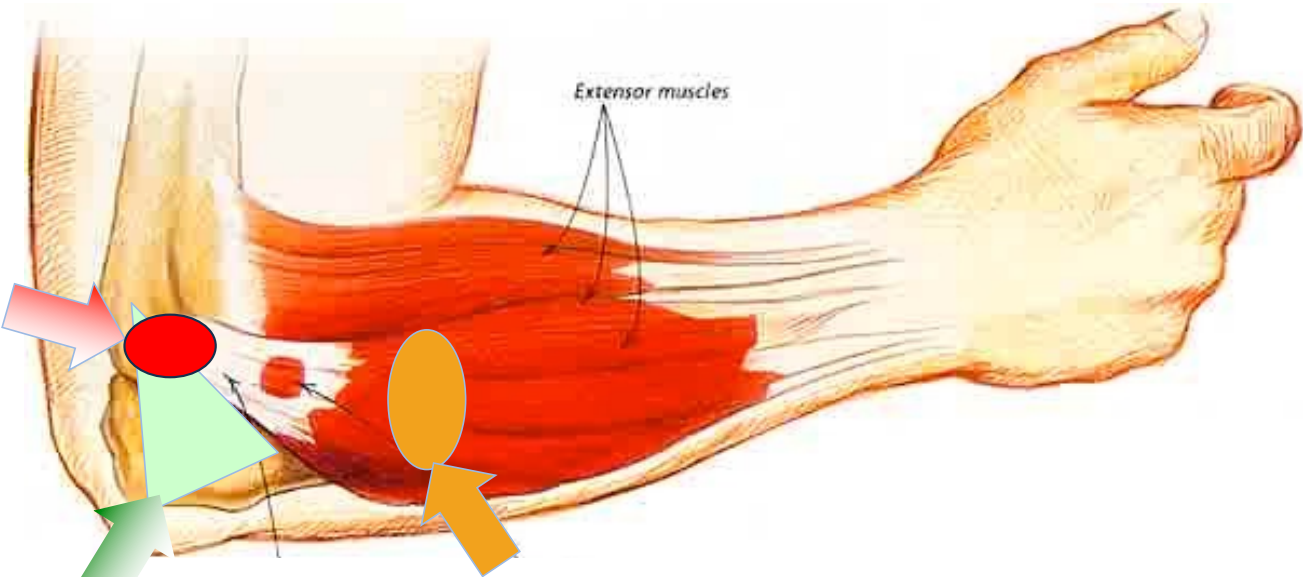
# What's New in Sports Medicine

- Hydrodilatation for Frozen Shoulder
- Posterior Interosseus Nerve Entrapment
- Platelet Rich Plasma: Best Practices





# A More Nuanced Approach to Lateral Elbow Pain



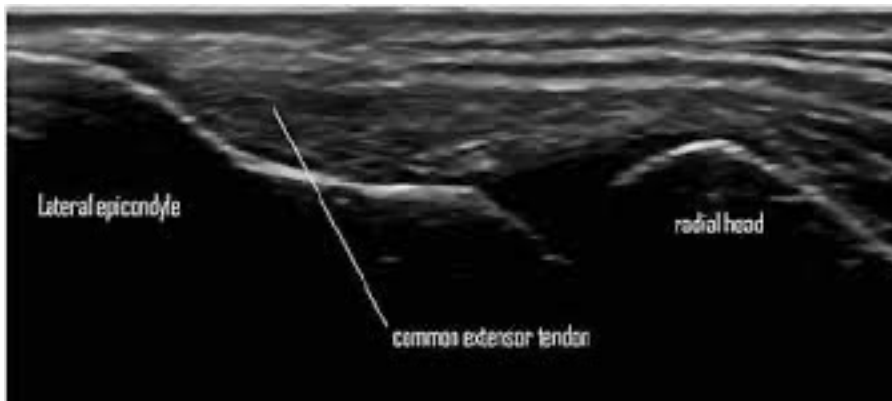**Lateral Epicondylitis  
(tennis elbow)**

**Intra-articular:  
OA, Infection  
Loose Body**

**PIN Syndrome  
(posterior interosseous n.)**

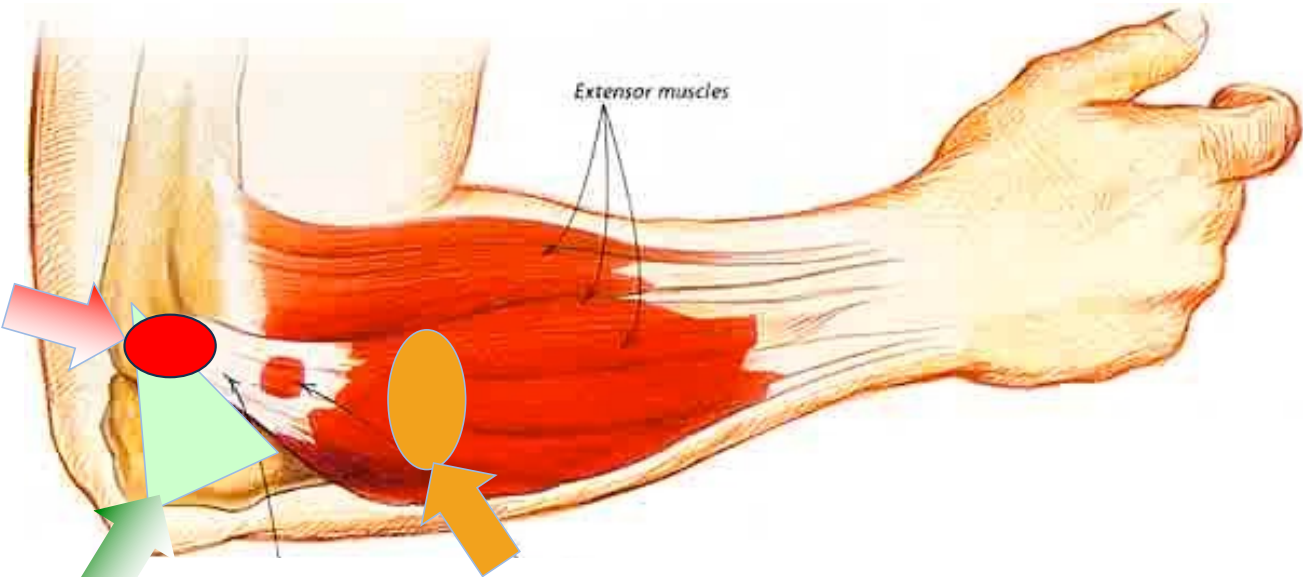


# “State of the Art” In Office Ultrasound Lateral



Tendinopathy Type	Tendinosis	Hyperemia	MSK-US
<b>Type 1</b> Normal	Negative	Negative	<p>LE R</p>
Image above: Lateral epicondyle (LE), Radial head (R), Common extensor tendon (Arrowheads)			
<b>Type 2</b> Inflammatory	Negative	<b>Positive</b>	<p>LE R</p>
Image above: Late Lateral epicondyle (LE), Radial head (R), hyperemia (red/orange areas)			
<b>Type 3</b> Degenerative	<b>Positive</b>	Negative	<p>LE R *</p>
Image above: Lateral epicondyle (LE), Radial head (R), Tendinosis (Asterisk)			
<b>Type 4</b> Inflammatory and Degenerative	<b>Positive</b>	<b>Positive</b>	<p>LE R * *</p>
Image above: Lateral epicondyle (LE), Radial head (R), Tendinosis (Asterisks), Hyperemia (red/orange areas)			

# A More Nuanced Approach to Lateral Elbow Pain

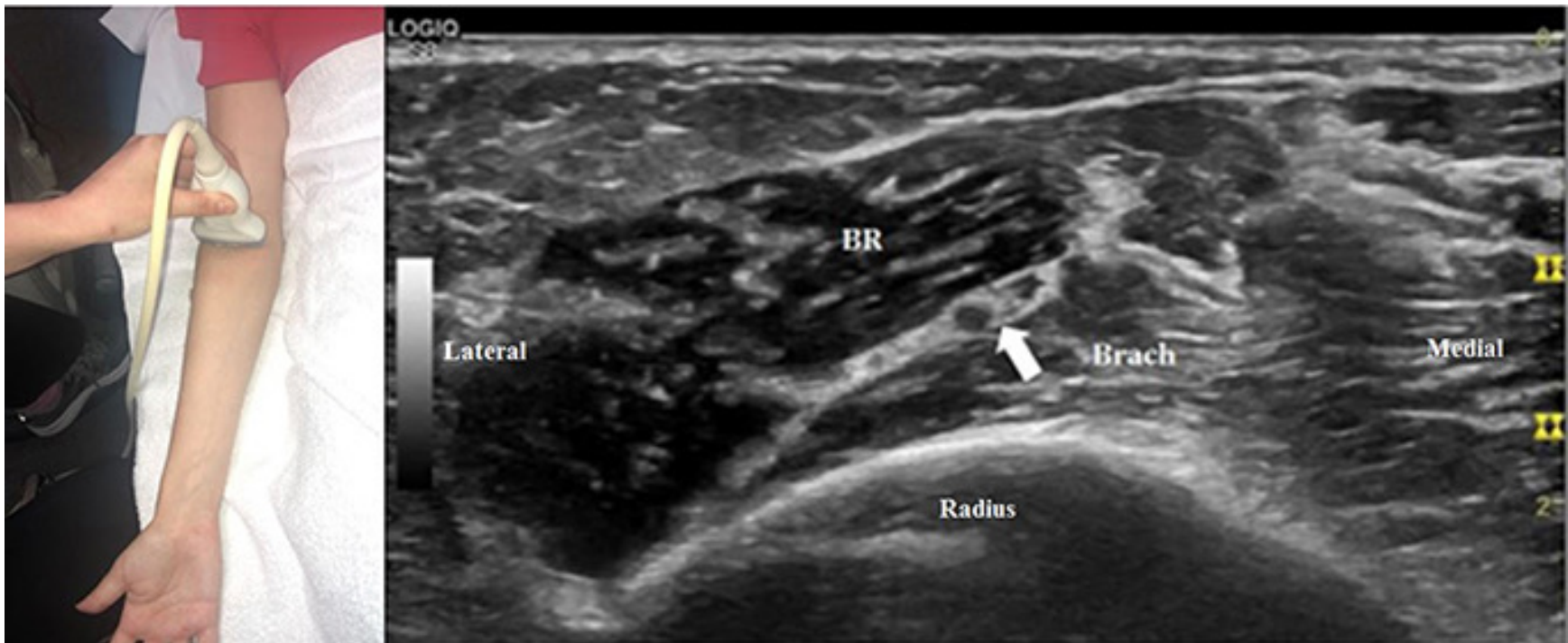


**Lateral Epicondylitis  
(tennis elbow)**

**Intra-articular:  
OA, Infection  
Loose Body**

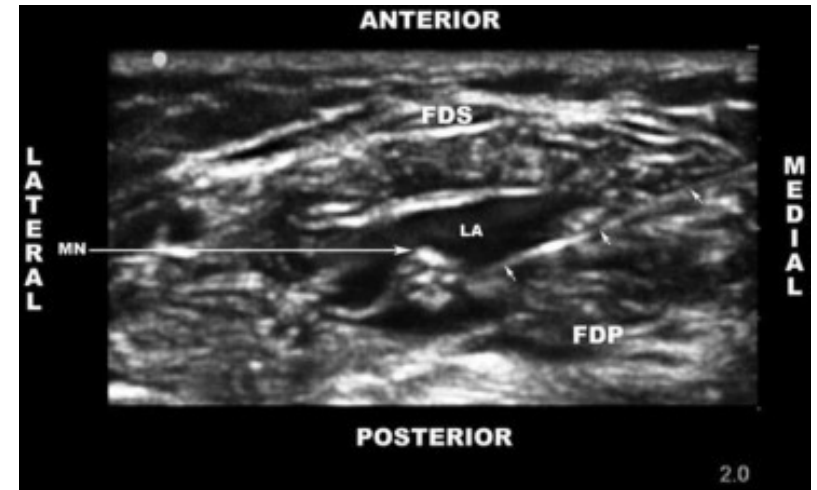
**PIN Syndrome  
(posterior interosseous n.)**

# Posterior Interosseous Nerve - Ultrasound



# Posterior Interosseous Nerve - Injection


- 40mg triamcinolone
- 3-4cc 0.5% lidocaine
- Circumferential halo
  
- Call patient in 2-3 days for report on effect
- If > 75%, wait for pain to recur (add home ex prog?)
- If pain recurs, D5W hydrodissection



- Don't forget to mention "drop wrist!"
- Goes away morning after

# What's New in Sports Medicine

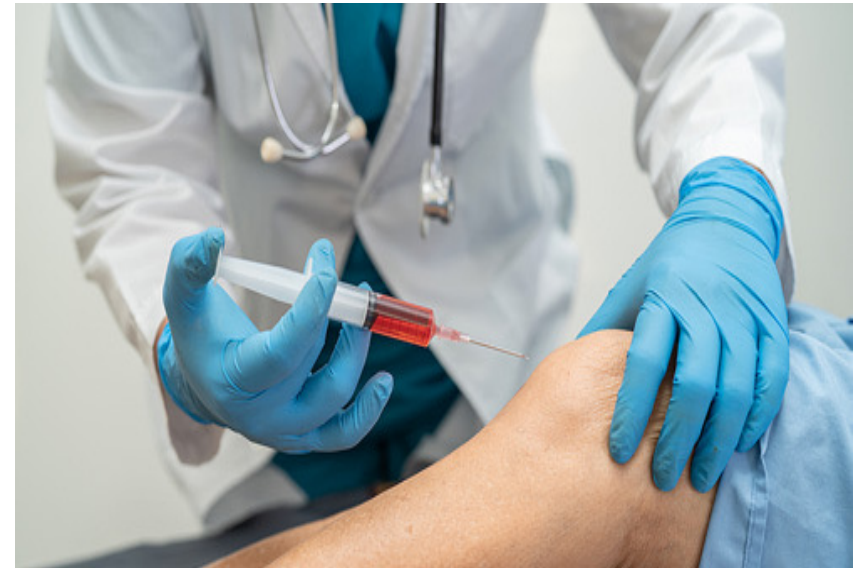- Hydrodilatation for Frozen Shoulder
- Posterior Interosseus Nerve Entrapment
- Platelet Rich Plasma: Best Practices





# Platelet Rich Plasma in Sports Medicine

- Controversial for many things
- Cash pay = always problematic
  - Tricare and Wellpay do cover PRP
- What does evidence say?



# Best Evidence for Common Conditions

## Good Evidence:

- ✓ Mild to Moderate Knee OA
  - Better in patients <50-60yo
- ✓ Lateral Epicondylitis
- ✓ Glut Med/Min tears (trochanteric pain)
- ✓ Chronic muscle tear/MT junction tear in athletes

## Less Evidence:

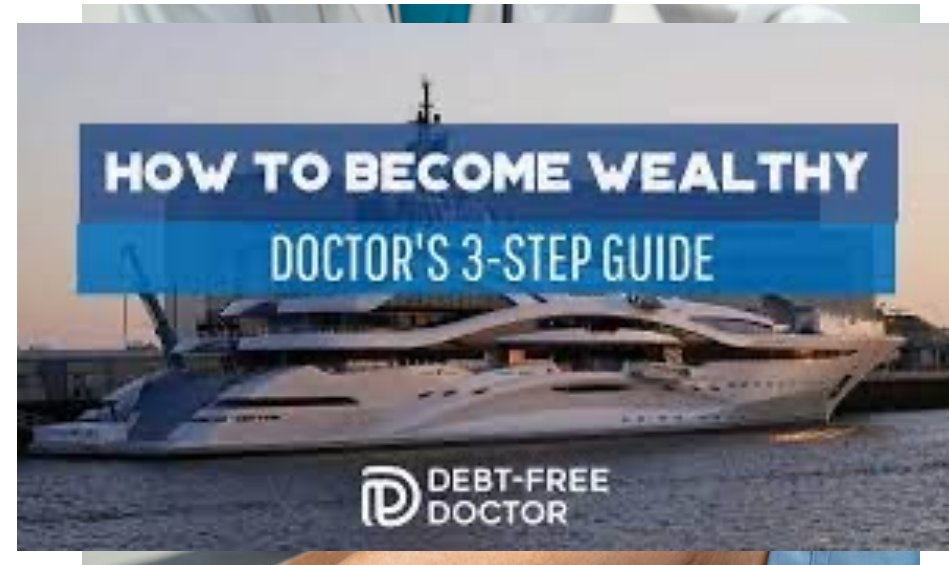- Plantar Fasciitis
- Patellar/Quat Tendinopathy
- Hip/Shoulder OA
- Rotator Cuff Tendinopathy



# Best Practices for MSK PRP Injections


## Look for:

- ✓ Ultrasound Guidance!
- ✓ Concentration 6-10X serum
- ✓ Leukocyte rich vs Leuk poor
- ✓ Experience
- ✓ Cost (>\$800/injection is a lot of boat...)



# What's New in Sports Medicine

- Hydrodilatation for Frozen Shoulder
- Posterior Interosseus Nerve Entrapment
- Platelet Rich Plasma: Best Practices





**Intermountain<sup>®</sup>  
Healthcare**

Ogden Area:

**801-38SPORT**

Anywhere in Utah:

**801-IHC-BONE**

## **What's New in Sports Medicine**

May 19, 2022

Ogden Surgical – Medical Society Conference

*Anthony Beutler, MD*

*Associate Medical Director & Fellowship Director, Sports Med*

*Intermountain Healthcare*

*[Anthony.Beutler@imail.org](mailto:Anthony.Beutler@imail.org)*

# **Questions?**